

Evidence-Based Midwifery Management of Premature Rupture of Membranes at Term Pregnancy in Primary Care: A Case Report

Aylinda Hrp¹, Riska Hutapea², Salwa Adya Mecca Saragih³, Lydia Riska Dini Pinem⁴,
Ninsah Mandala Putri Sembiring⁵, Modesta Marpaung⁶

Program Studi Kebidanan Program Sarjana, STIKes Mitra Husada Medan, Indonesia

Article History

Received : June 30, 2026

Revised : July 09, 2026

Accepted : July 10, 2026

Published : July 10, 2026

Corresponding author*:

aylindahrp1605@gmail.com

Cite This Article [APA Style]

Hrp, A., Hutapea, R., Saragih, S. A. M., Pinem, L. R. D., Sembiring, N. M. P., & Marpaung, M. (2026). Evidence-Based Midwifery Management of Premature Rupture of Membranes at Term Pregnancy in Primary Care: A Case Report. *Jurnal Kesehatan Dan Kedokteran*, 5(2), 794–807.

DOI:

<https://doi.org/10.56127/jukeke.v5i2.2893>

Abstract: Premature Rupture of Membranes (PROM) is a common obstetric complication associated with maternal infection, neonatal morbidity, and adverse pregnancy outcomes if not managed promptly. Comprehensive and evidence-based midwifery care is essential to improve maternal and neonatal safety, particularly in primary healthcare settings. **Objective:** This case report aimed to describe the implementation of evidence-based midwifery management for a woman with term PROM using Helen Varney's Seven-Step Midwifery Management framework. **Methods:** A descriptive case report design was employed involving a 26-year-old primigravida (G1P0A0) at 39 weeks of gestation who presented with spontaneous rupture of membranes before the onset of regular uterine contractions. Clinical data were collected through patient interviews, physical and obstetric examinations, labor observations, medical records, and neonatal assessments. Data were analyzed descriptively using a narrative approach based on Helen Varney's Seven-Step Midwifery Management and interpreted according to current evidence-based recommendations. **Findings:** Following confirmation of PROM, continuous maternal and fetal monitoring was performed until spontaneous labor occurred. The patient delivered a healthy female infant vaginally with a birth weight of 3,000 g, body length of 49 cm, and an Apgar score of 9. The placenta was delivered completely, and the mother remained clinically stable despite experiencing a second-degree perineal laceration that was successfully repaired. No immediate maternal or neonatal complications were observed. **Implications:** The findings demonstrate that systematic assessment, continuous monitoring, and evidence-based midwifery management can support favorable maternal and neonatal outcomes in women with PROM and may strengthen the quality of maternity care in primary healthcare facilities. **Originality:** This report highlights the practical implementation of Helen Varney's Seven-Step Midwifery Management in a term PROM case within a primary healthcare setting, providing a structured example of evidence-based midwifery practice.

Keywords: Premature rupture of membranes; evidence-based midwifery; Helen Varney; primary healthcare; case report.

INTRODUCTION

Premature Rupture of Membranes (PROM) remains an important obstetric complication in maternal and neonatal health services because it is associated with an increased risk of infection, preterm birth, and impaired fetal well-being. PROM refers to the rupture of the foetal membranes before the onset of labor contractions ([American](#)

[College of & Gynecologists, 2020](#)). When this condition occurs before 37 weeks of gestation, it is referred to as Preterm Prelabor Rupture of Membranes (PPROM) ([Garg & Jaiswal, 2023](#)). The risk of complications becomes greater in preterm pregnancies because PROM is closely related to prematurity, oligohydramnios, intrauterine infection, and impaired neonatal adaptation ([Goodfellow et al., 2024](#)).

In primary healthcare settings, PROM is a clinical condition that requires prompt response because midwives and frontline healthcare providers often serve as the first professionals responsible for initial assessment, identification of danger signs, monitoring of maternal and fetal conditions, and referral decision-making. Delayed diagnosis may increase the risk of chorioamnionitis and postpartum endometritis ([Thomson, 2019](#)). In fetuses and neonates, PROM may also increase the risk of asphyxia, neonatal sepsis, umbilical cord prolapse, and perinatal mortality ([Jain et al., 2022](#)). Therefore, systematic, evidence-based, and well-documented midwifery care is essential to support maternal and neonatal safety in PROM cases.

Previous studies on PROM can be grouped into three main areas. The first group discusses risk factors for PROM, including previous PROM, genital infection, anemia, poor nutritional status, smoking, low body mass index, multiple pregnancy, cervical abnormalities, and polyhydramnios. A meta-analysis by Lin showed that PROM is multifactorial and influenced by biological, obstetric, and environmental factors ([Lin et al., 2024](#)). Vaginal microbiota studies also indicate that dysbiosis and altered genital tract microbial composition may contribute to membrane weakening and ascending infection ([Borges et al., 2023](#)). Other findings show that obstetric history and certain maternal conditions play an important role in increasing the risk of PROM ([Wahabi et al., 2024](#)). However, studies in this category generally emphasize associations between variables rather than explaining how these risk factors are assessed and followed up in individual midwifery care.

The second group focuses on the diagnosis and clinical management of PROM, including sterile speculum examination, restriction of digital vaginal examinations, monitoring for signs of infection, antibiotic administration, corticosteroid therapy in preterm PROM, and decision-making between active and expectant management based on gestational age and the patient's clinical condition. ACOG emphasizes that PROM management should consider gestational age, signs of infection, maternal condition, and fetal well-being ([American College of & Gynecologists, 2020](#)). Garg and Jaiswal explain

that accurate diagnosis and appropriate timing of delivery are key components in reducing the risk of complications (Garg & Jaiswal, 2023). Ronzoni further recommend structured clinical assessment and individualized management in PPRM (Ronzoni et al., 2022). Evidence on antibiotic prophylaxis also suggests that appropriate antibiotic regimens may improve selected maternal and neonatal outcomes in PPRM (Lorthe et al., 2022). Nevertheless, most discussions in this area are derived from clinical guidelines or hospital-based studies, which do not fully reflect the implementation of midwifery care in primary healthcare facilities.

The third group examines maternal and neonatal outcomes associated with PROM. Preterm PROM is associated with an increased risk of respiratory distress syndrome, low birth weight, and the need for neonatal intensive care (González-Mesa et al., 2021). Yan reported that gestational age at membrane rupture and latency period influence neonatal outcomes (Yan et al., 2022). Zhuang also found that longer latency after term PROM may increase the risk of neonatal infectious morbidity (Zhuang et al., 2022). In extremely preterm infants, PROM has been associated with adverse neonatal outcomes requiring intensive monitoring (Cao et al., 2023). Beyond clinical consequences, PROM may also impose psychological burdens on mothers and families because of uncertainty regarding fetal condition and the risk of prematurity (Challacombe et al., 2025). However, case reports that connect assessment, diagnosis, intervention, and evaluation of midwifery care with patient clinical outcomes remain limited, particularly those using Helen Varney's seven-step midwifery management approach.

Based on this gap, this article aims to describe the management of midwifery care for a woman in labor with Premature Rupture of Membranes at Rizky Clinic, Medan. Specifically, this article discusses the assessment process, identification of diagnoses and potential problems, care planning, implementation of interventions, and evaluation of care outcomes based on a systematic and evidence-based midwifery management approach.

This article argues that the implementation of comprehensive midwifery care in PROM cases can accelerate risk detection, prevent delays in management, and support better maternal and neonatal outcomes. Therefore, this case report is expected to provide a practical contribution to strengthening midwifery services in primary healthcare facilities, particularly in managing PROM safely, systematically, and according to established standards.

RESEARCH METHOD

This study employed a descriptive case report design to describe the comprehensive midwifery management of a woman diagnosed with Premature Rupture of Membranes (PROM). The unit of analysis was a single obstetric case involving Mrs. S, a 26-year-old primigravida (G1P0A0) at 39 weeks of gestation who was admitted to Rizky Clinic, Medan, Indonesia. The case focused on the intrapartum management of PROM, beginning from the initial assessment, confirmation of diagnosis, maternal and fetal monitoring, delivery process, neonatal assessment, and immediate postpartum evaluation.

A descriptive case report design was selected because it allows an in-depth presentation of clinical findings, diagnostic reasoning, midwifery interventions, and maternal-neonatal outcomes in a real clinical setting. This approach is appropriate for documenting the implementation of Helen Varney’s Seven-Step Midwifery Management, particularly in cases requiring continuous assessment, early risk detection, and timely clinical decision-making. The case report design also enables comparison between actual clinical practice and evidence-based recommendations for PROM management.

The data used in this case report were obtained from primary and secondary clinical sources. Primary data were collected through direct patient interview, physical examination, obstetric assessment, fetal heart rate monitoring, vaginal examination based on clinical indication, and observation during the first to fourth stages of labor. Secondary data were obtained from medical records, delivery documentation, neonatal assessment forms, and institutional clinical notes.

Table 1. Sources of Clinical Data Used in the Case Report

Data Source	Variables Collected	Collection Method
Patient interview	Chief complaint, obstetric history, pregnancy history, fetal movement, anxiety level	Direct interview
Physical examination	General condition, vital signs, body weight, height, maternal physical findings	Clinical examination
Obstetric assessment	Fundal height, fetal presentation, fetal position, estimated fetal weight, uterine contraction	Leopold maneuver and abdominal examination
Fetal monitoring	Fetal heart rate and fetal well-being	Auscultation
Vaginal examination	Cervical dilatation, membrane status, fetal station, presentation	Examination based on clinical indication
Labor observation	Labor progress from stage I to stage IV, maternal response, uterine contraction	Continuous clinical observation
Delivery documentation	Mode of delivery, time of birth, placental completeness, perineal laceration	Clinical record review

Data Source	Variables Collected	Collection Method
Neonatal assessment	Birth weight, body length, Apgar score, immediate neonatal adaptation	Newborn examination
Medical records	Supporting clinical notes and institutional documentation	Document review

Data collection was conducted prospectively from the patient’s admission to the immediate postpartum period. The patient arrived at 22:00 WIB on May 12, 2026, with a complaint of clear fluid leakage from the birth canal for approximately one hour before admission. Clinical information was recorded using standardized midwifery assessment forms. The data collection process included subjective assessment, objective examination, diagnosis formulation, identification of potential problems, care planning, implementation of interventions, and evaluation of maternal and neonatal outcomes. Patient identity was anonymized to maintain confidentiality and comply with ethical principles for clinical case reporting.

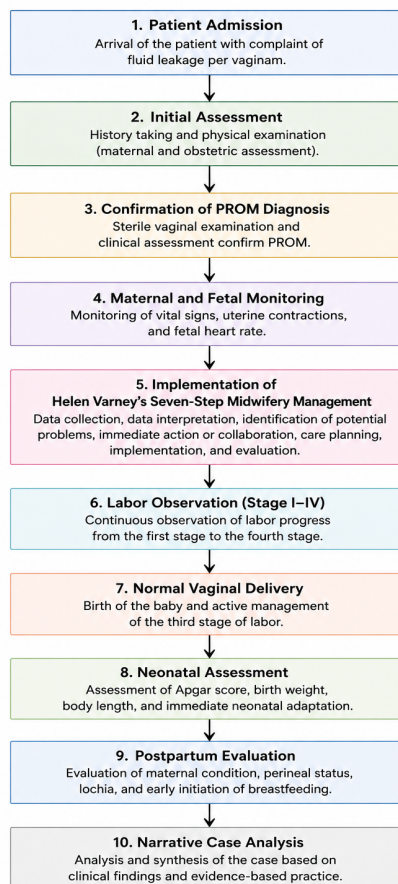


Figure 1. Flowchart of Data Collection and Midwifery Management

The collected data were analyzed descriptively using a narrative case analysis approach. Clinical findings were organized according to Helen Varney's Seven-Step Midwifery Management framework, consisting of data collection, data interpretation, identification of potential problems, immediate action or collaboration, care planning, implementation, and evaluation. The management process and clinical outcomes were then compared with contemporary evidence-based recommendations for PROM to assess the appropriateness of midwifery care provided in a primary healthcare setting.

RESULT

CASE PRESENTATION

Patient Characteristics and Initial Clinical Findings

A 26-year-old woman (Mrs. S), gravida 1 para 0 abortus 0 (G1P0A0), at 39 weeks of gestation, presented to the delivery room of Rizky Clinic, Medan, on May 12, 2026, at 22:00 WIB. The patient complained of a sudden leakage of clear fluid from the birth canal approximately one hour before admission. The fluid continued to leak continuously, while regular uterine contractions had not yet developed. Fetal movement was still perceived actively by the mother. The patient had attended routine antenatal care throughout pregnancy and had no history of anemia, hypertension, diabetes mellitus, epilepsy, heart disease, or other pregnancy complications. This was her first pregnancy.

On physical examination, the patient appeared in good general condition and was fully conscious with mild anxiety. Vital signs were within normal limits, including blood pressure of 120/80 mmHg, pulse rate of 82 beats/minute, respiratory rate of 20 breaths/minute, and body temperature of 36.8°C. Obstetric examination revealed a fundal height of approximately 33 cm, longitudinal fetal lie, cephalic presentation, left occiput anterior position, fetal head at the pelvic inlet, estimated fetal weight of approximately 3,100 g, and fetal heart rate of 140 beats/minute. Sterile vaginal examination demonstrated clear amniotic fluid leakage with the cervix remaining closed (0 cm dilatation), soft cervical consistency, and intact maternal condition, leading to the diagnosis of Premature Rupture of Membranes (PROM).

The initial clinical assessment was performed to determine maternal condition, fetal well-being, and the presence of ruptured membranes. The main findings at admission are summarized in Table 2.

Table 2. Initial Clinical Characteristics of the Patient

Variable	Findings
Maternal age	26 years
Gravidity/Parity	G1P0A0
Gestational age	39 weeks
Chief complaint	Clear fluid leakage for approximately one hour
General condition	Good
Blood pressure	120/80 mmHg
Pulse	82 beats/minute
Respiratory rate	20 breaths/minute
Body temperature	36.8°C
Fundal height	33 cm
Fetal presentation	Cephalic
Estimated fetal weight	±3,100 g
Fetal heart rate	140 beats/minute
Cervical dilatation	0 cm
Membrane status	Ruptured
Clinical diagnosis	Premature Rupture of Membranes

As shown in Table 2, the patient was hemodynamically stable at admission, with normal vital signs and reassuring fetal heart rate. The presence of clear amniotic fluid leakage and closed cervical dilatation supported the diagnosis of Premature Rupture of Membranes before the onset of active labor.

Intrapartum Midwifery Management

Following confirmation of PROM, the patient was admitted for observation. Maternal vital signs, fetal heart rate, uterine contractions, and the characteristics of amniotic fluid were monitored regularly. During the observation period, uterine contractions gradually became regular. At full cervical dilatation, the patient reported an urge to bear down accompanied by pressure in the vaginal and anal regions. Uterine contractions occurred four times every ten minutes with a duration of 45–60 seconds, while fetal heart rate remained 140 beats/minute.

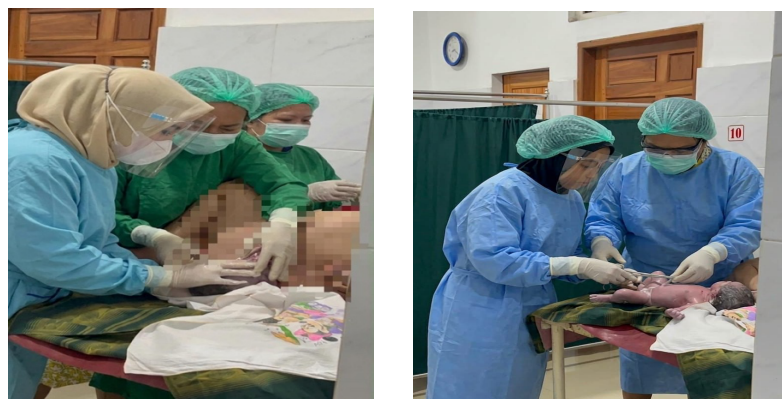


Figure 2. Initial assessment and intrapartum management of a patient with PROM

The labor progressed normally. At 09:00 WIB, the patient delivered a live female infant through spontaneous vaginal delivery. The newborn cried immediately after birth, demonstrated active spontaneous movement, and had a normal skin color. The infant weighed 3,000 g and measured 49 cm in length, with an Apgar score of 9 at the first assessment.

Maternal and Neonatal Outcomes

Following delivery, the placenta and fetal membranes were delivered completely. Examination of the placenta showed complete maternal and fetal surfaces with intact membranes and an approximate placental diameter of 20 cm. The umbilical cord measured approximately 50 cm in length and contained normal Wharton's jelly. The uterus was well contracted, the bladder was empty, and vaginal bleeding remained within normal limits.

Postpartum examination identified a second-degree perineal laceration requiring repair with ten sutures. During the fourth stage of labor, maternal vital signs remained stable, including blood pressure of 120/80 mmHg, pulse rate of 84 beats/minute, respiratory rate of 20 breaths/minute, and body temperature of 36.8°C. The uterine fundus was palpated two fingerbreadths below the umbilicus with good uterine contraction. Both mother and newborn remained in stable condition and were transferred to the postpartum ward for continued observation. After delivery, maternal and neonatal outcomes were evaluated to assess the immediate results of midwifery care and to identify any postpartum complications. The outcomes observed after birth are presented in Table 3.

Table 3. Maternal and Neonatal Outcomes

Variable	Findings
Mode of delivery	Spontaneous vaginal delivery
Time of delivery	09:00 WIB
Neonatal sex	Female
Birth weight	3,000 g
Birth length	49 cm
Apgar score	9
Placenta	Complete
Placental diameter	Approximately 20 cm
Umbilical cord length	Approximately 50 cm
Perineal laceration	Second degree
Perineal repair	Ten sutures
Uterine contraction	Good
Maternal condition	Stable
Neonatal condition	Stable

Table 3 shows that the delivery resulted in favorable maternal and neonatal outcomes. The newborn had good immediate adaptation, as indicated by spontaneous crying, active movement, normal coloration, and an Apgar score of 9. The mother remained stable after delivery, with adequate uterine contraction and no reported abnormal postpartum bleeding. The second-degree perineal laceration was repaired appropriately.



Figure 3. Delivery and Immediate Newborn Care

Clinical Timeline

A chronological timeline was constructed to provide a clear overview of the patient’s clinical course from admission to postpartum observation. This timeline helps demonstrate the sequence of assessment, diagnosis, labor progress, delivery, and postpartum management.

Table 4. Clinical Timeline

Time	Clinical Findings	Clinical Management
22:00	Admission with clear amniotic fluid leakage	Initial assessment and physical examination
22:15	PROM confirmed by vaginal examination	Maternal and fetal observation
Overnight	Regular uterine contractions developed	Continuous labor monitoring
09:00	Spontaneous vaginal delivery	Standard midwifery care
09:00	Placenta delivered completely	Third-stage labor management
09:15	Second-degree perineal laceration identified	Perineal suturing
Postpartum	Mother and newborn stable	Postpartum observation

As summarized in Table 4, the clinical course progressed from PROM without regular contractions to spontaneous labor and uncomplicated vaginal delivery. Postpartum

observation showed that both mother and newborn remained stable, supporting the effectiveness of continuous monitoring and timely midwifery management.

DISCUSSION

The present case demonstrated that comprehensive midwifery management contributed to favorable maternal and neonatal outcomes in a woman with Premature Rupture of Membranes (PROM) at term pregnancy. The patient presented with spontaneous leakage of clear amniotic fluid before the onset of regular uterine contractions, while maternal vital signs and fetal heart rate remained within normal limits. Continuous observation enabled the identification of spontaneous labor progression, resulting in an uncomplicated vaginal delivery of a healthy female infant with an Apgar score of 9. Following delivery, the placenta was expelled completely, uterine contraction remained adequate, and both the mother and newborn were clinically stable during the immediate postpartum period.

The favorable clinical outcome observed in this case may be explained by several important factors. First, the patient sought medical attention shortly after membrane rupture, allowing prompt confirmation of PROM and immediate initiation of maternal and fetal monitoring. Second, the absence of maternal fever, abnormal fetal heart rate, or other clinical indicators of infection supported expectant management until spontaneous labor developed. Third, the implementation of systematic midwifery care based on Helen Varney's Seven-Step Midwifery Management facilitated comprehensive assessment, early identification of potential complications, timely clinical decision-making, and continuous evaluation throughout labor. Collectively, these factors likely contributed to preventing maternal and neonatal complications frequently associated with prolonged rupture of membranes.

The findings of this case are consistent with current international recommendations regarding the management of term PROM. The American College of Obstetricians and Gynecologists recommends careful maternal and fetal assessment immediately after membrane rupture to determine gestational age, exclude infection, evaluate fetal well-being, and establish an appropriate management strategy ([American College of & Gynecologists, 2020](#)). Similarly, the Royal College of Obstetricians and Gynaecologists emphasizes continuous maternal and fetal surveillance while minimizing unnecessary vaginal examinations to reduce the risk of ascending infection ([Thomson, 2019](#)). Previous

observational studies have also demonstrated that appropriate monitoring and timely obstetric management are associated with favorable maternal and neonatal outcomes in PROM cases (Goodfellow et al., 2024; Wahabi et al., 2024). The present case supports these recommendations by demonstrating successful implementation of evidence-based midwifery management in a primary healthcare setting.

An important contribution of this report lies in documenting the practical application of Helen Varney's Seven-Step Midwifery Management in the management of PROM within a primary midwifery clinic. While most previous studies have primarily evaluated risk factors, clinical guidelines, or maternal-neonatal outcomes at the population level, relatively few publications describe how comprehensive midwifery management is implemented throughout the continuum of care in an individual patient. Therefore, this case provides practical evidence that structured clinical reasoning and continuous monitoring can be effectively integrated into routine midwifery practice to support safe childbirth in women experiencing PROM.

Despite the favorable outcome, PROM remains associated with potentially serious maternal and neonatal complications, including chorioamnionitis, neonatal sepsis, umbilical cord prolapse, and postpartum infection if diagnosis or management is delayed. Consequently, comprehensive assessment alone is insufficient without continuous clinical vigilance throughout labor. The successful outcome in this patient should not be interpreted as indicating that all PROM cases can be managed similarly, as management decisions should always consider gestational age, duration of membrane rupture, maternal condition, fetal status, and the availability of referral services.

The findings of this case have practical implications for maternal healthcare services, particularly in primary healthcare facilities. Midwives should strengthen early recognition of PROM, perform comprehensive maternal and fetal assessment immediately after diagnosis, limit unnecessary vaginal examinations, maintain strict aseptic techniques, and conduct continuous monitoring until delivery. Furthermore, standardized implementation of Helen Varney's Seven-Step Midwifery Management may improve documentation quality, clinical decision-making, and continuity of care. Future case reports and multicenter observational studies are recommended to further evaluate the effectiveness of evidence-based midwifery management strategies in improving maternal and neonatal outcomes among women with PROM.

CONCLUSION

This case report demonstrates that comprehensive and systematic midwifery management contributed to favorable maternal and neonatal outcomes in a woman with Premature Rupture of Membranes (PROM) at term pregnancy. Early identification of PROM, continuous maternal and fetal monitoring, timely clinical decision-making, and appropriate intrapartum care enabled spontaneous vaginal delivery without major complications. The mother remained hemodynamically stable throughout labor and the immediate postpartum period, while the newborn was delivered in good condition with satisfactory neonatal adaptation.

The primary contribution of this case report lies in documenting the practical implementation of Helen Varney's Seven-Step Midwifery Management in the care of PROM within a primary healthcare setting. This report provides a structured description of clinical assessment, diagnosis, intervention, implementation, and evaluation based on evidence-informed midwifery practice. The findings highlight the importance of integrating standardized midwifery management with continuous clinical observation to support safe labor and improve maternal and neonatal outcomes, particularly in primary maternity services.

This report is limited by its presentation of a single clinical case from one healthcare facility, which restricts the generalizability of its findings to broader populations. In addition, the absence of long-term maternal and neonatal follow-up limits the evaluation of outcomes beyond the immediate postpartum period. Future studies involving larger case series, multicenter investigations, or prospective observational designs are recommended to further evaluate the effectiveness of evidence-based midwifery management for women with PROM across different clinical settings.

REFERENCES

- American College of, O., & Gynecologists. (2020). Prelabor rupture of membranes: ACOG Practice Bulletin No. 217. *Obstetrics & Gynecology*, *135*(3), e80-e97. <https://doi.org/10.1097/AOG.0000000000003700>
- Borges, L. G. A., Souza, R. T., Cecatti, J. G., Passini, R., Pacagnella, R. C., Nomura, M. L., & Costa, M. L. (2023). Vaginal and neonatal microbiota in pregnant women with preterm prelabor rupture of membranes. *BMC Medicine*, *21*, 104. <https://doi.org/10.1186/s12916-023-02805-x>
- Cao, J. K., Liu, C. G., Wang, D., & Li, Q. P. (2023). Impact of premature rupture of membranes on clinical outcomes of extremely premature infants: A propensity score

- matching study. *Frontiers in Pediatrics*, *11*, 1144373. <https://doi.org/10.3389/fped.2023.1144373>
- Challacombe, F. L., Goodfellow, L., & Care, A. (2025). Preterm premature rupture of the membranes (PPROM): Psychological impact and care experiences of women and families. *BJOG: An International Journal of Obstetrics & Gynaecology*. <https://doi.org/10.1111/1471-0528.18175>
- Garg, A., & Jaiswal, A. (2023). Evaluation and management of premature rupture of membranes: A review article. *Cureus*, *15*(3), e36615. <https://doi.org/10.7759/cureus.36615>
- González-Mesa, E., Blasco-Alonso, M., Benítez, M. J., Gómez, C., Cazorla, O., & Mozas, J. (2021). Obstetric and perinatal outcomes after very early preterm premature rupture of membranes (PPROM): A retrospective analysis over the period 2000–2020. *Medicina*, *57*(5), 469. <https://doi.org/10.3390/medicina57050469>
- Goodfellow, L., Care, A., Curran, C., Roberts, D., Turner, M. A., Knight, M., & Alfirevic, Z. (2024). Preterm prelabour rupture of membranes before 23 weeks' gestation: A prospective observational study. *BMJ Medicine*, *3*(1), e000729. <https://doi.org/10.1136/bmjmed-2023-000729>
- Jain, S., Gupta, A., & Gupta, S. (2022). Maternal and neonatal outcomes in premature rupture of membranes. *Journal of Family Medicine and Primary Care*, *11*(8), 4623-4628. https://doi.org/10.4103/jfmpe.jfmpe_2304_21
- Lin, D., Hu, B., Xiu, Y., Ji, R., Zeng, H., Chen, H., & Wu, Y. (2024). Risk factors for premature rupture of membranes in pregnant women: A systematic review and meta-analysis. *BMJ Open*, *14*, e077727. <https://doi.org/10.1136/bmjopen-2023-077727>
- Lorthe, E., Ancel, P. Y., Torchin, H., Kaminski, M., Langer, B., Subtil, D., & Kayem, G. (2022). Antibiotic prophylaxis in preterm premature rupture of membranes at 24–31 weeks' gestation: Perinatal and 2-year outcomes in the EPIPAGE-2 cohort. *BJOG: An International Journal of Obstetrics & Gynaecology*, *129*(9), 1560-1570. <https://doi.org/10.1111/1471-0528.17081>
- Ronzoni, S., Boucoiran, I., Yudin, M. H., Money, D. M., & van Schalkwyk, J. (2022). Guideline No. 430: Diagnosis and management of preterm prelabour rupture of membranes. *Journal of Obstetrics and Gynaecology Canada*, *44*(11), 1193-1208.e1191. <https://doi.org/10.1016/j.jogc.2022.08.010>
- Thomson, A. J. (2019). Care of women presenting with suspected preterm prelabour rupture of membranes from 24+0 weeks of gestation (Green-top Guideline No. 73). *BJOG: An International Journal of Obstetrics & Gynaecology*, *126*(9), e152-e166. <https://doi.org/10.1111/1471-0528.15803>
- Wahabi, H., Fayed, A., Esmaeil, S., Alzeidan, R., Mandil, A., & Alodhayani, A. (2024). Predictors and outcomes of premature rupture of membranes in singleton pregnancies: A cohort study. *BMC Pregnancy and Childbirth*, *24*, 855. <https://doi.org/10.1186/s12884-024-07020-x>
- Yan, C., Deng, C., Jia, X., & Zhang, L. (2022). Analysis of maternal and neonatal outcomes of patients with preterm prelabor rupture of membranes. *Computational and*

Mathematical Methods in Medicine, 2022, 8705005.
<https://doi.org/10.1155/2022/8705005>

Zhuang, L., Xia, W., Chen, Y., Zhang, Y., & Xu, X. (2022). Latency period of premature rupture of membranes at term and the risk of neonatal infectious diseases. *Scientific Reports*, 12, 12275. <https://doi.org/10.1038/s41598-022-16593-6>